

# Pathologic Changes in Testis and Epididymis of Infertile Leprotic Males<sup>1</sup>

A. A. Ibrahim, H. A. Awad, B. A. Metawi and T. A. Y. Hamada<sup>2</sup>

Although testicular involvement in leprosy has long been known to be very common<sup>(12)</sup> and many investigators have studied the histopathologic changes that occur in the testes in various types of leprosy<sup>(2-7, 9, 11)</sup>, such histopathologic observations have not been related to presence or absence of sterility. The present study was undertaken to elucidate more clearly the cause of sterility in male leprosy patients having testicular and/or epididymal affection.

## MATERIALS AND METHODS

The study was performed on 32 patients known to have leprosy and under treatment with antileprotic drugs. Most of the patients were diagnosed as lepromatous or borderline lepromatous, only two patients were diagnosed as tuberculoid. Actually, the first diagnosis of the patients and the typing were done before the patients came to us, since they came seeking advice for their infertility years after first starting their treatment for leprosy. All were sterile and were seeking advice respecting their infertility. Their average age was 39 years, the youngest being 35 and the oldest 51. The duration of their disease ranged from 7 to 20 years since first discovered. All patients were married and seven had from one to three children before they contracted the disease. The others had no children.

The testis was small and atrophic on both sides in 26 cases and more or less normal in size in the remaining six patients. The tail of the epididymis was nodular in ten patients and in five of these the head of the epididymis was distended, whereas in the other five cases the epididymal head and body were collapsed (Table 1).

<sup>1</sup>Received for publication 16 June 1978.

<sup>2</sup>A. A. Ibrahim, M.D., Professor of Andrology; H. A. Awad, M.D., Lecturer of Andrology; B. A. Metawi, M.D., Lecturer of Andrology; T. A. Y. Hamada, M.D., Lecturer of Andrology; all from the V.D. and Andrology Section, Faculty of Medicine, Cairo University, Egypt.

Repeated semen analysis was done for each patient. A wedge testicular biopsy was taken from one testis from each patient; in addition, a biopsy was taken from both the head and tail of the epididymis from each of ten patients presenting nodules in the epididymis. The biopsy specimens were fixed in Bouin's fixative and processed for histopathologic examination. Paraffin embedded sections were cut at 5-7 $\mu$  thickness and stained with hematoxylin-eosin and Ziehl-Neelsen stains.

## RESULTS

**Semen analysis.** Azoospermia was found in 31 cases while in the remaining case the semen count was 2,000,000 per ml, and sperm motility was 10% three hours after ejaculation.

**Testicular biopsies.** In 27 cases there was definite microscopic evidence of severe inflammatory involvement of the testis regardless of its size and the semen picture. The histopathologic changes varied markedly. These changes could not be classified into definite phases since more than one appearance could be seen in the same specimen.

The mildest form of testicular affection was a combination of spermatogenic arrest and moderate to severe hyalinization of the seminiferous tubules. In addition, there was moderate increase in the interstitial cells with clumps in some areas. Blood vessel walls

TABLE 1. *Appearance of the testis and epididymis.*

| Description of testis and epididymis                                  | No. of cases |
|---|--------------|
| Small atrophic testis and epididymis                                  | 22           |
| Small atrophic testis with nodular epididymal tail                    | 2            |
| Normal testis with nodular epididymal tail and atrophic head and body | 3            |
| Normal testis with nodular epididymal tail and distended head         | 5            |

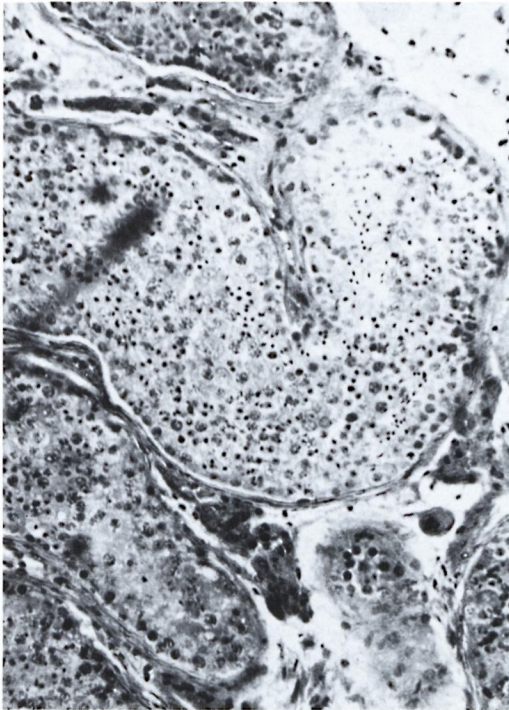


FIG. 1. Testicular biopsy from an azoospermic leprotic man showing normal seminiferous tubules with normal spermatogenesis.

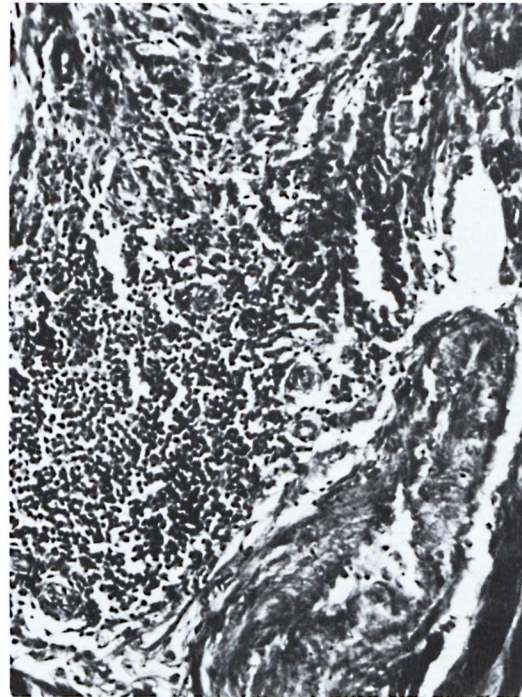


FIG. 2. Biopsy from a nodule in the tail of the epididymis of the same case as Figure 1, showing dense cellular infiltration outside the wall of the epididymal tubule causing marked compression and obliteration of the lumen.

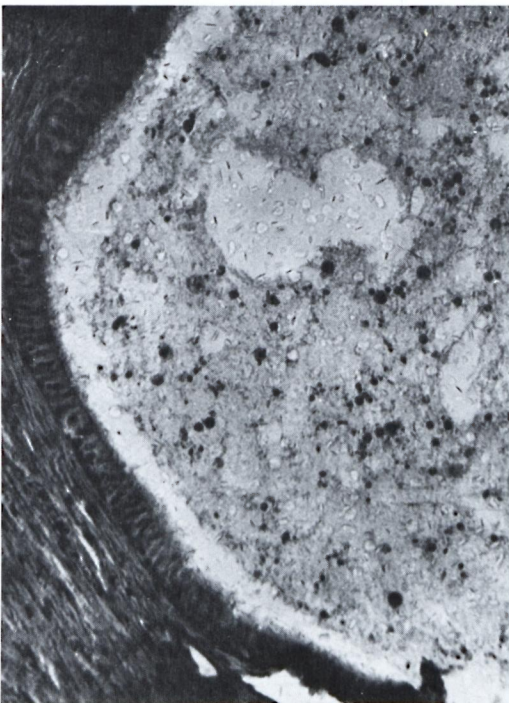


FIG. 3. Biopsy from the head of the epididymis of the same case showing sperm and spermatogenic cells inside.

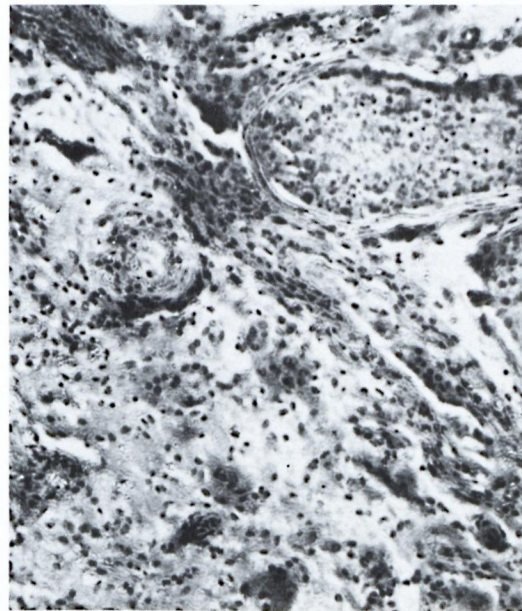


FIG. 4. Testicular biopsy from the oligospermic leprotic case showing spermatogenic arrest in one tubule and hyalinization in the rest. There is mild cellular infiltration and an increase in the interstitial cells with some clumping.

Centro de Estudios  
r. Reinaldo Quagliato

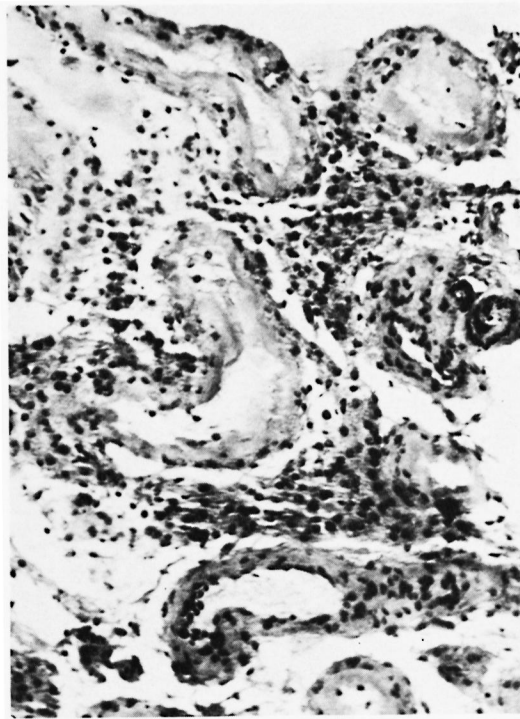


FIG. 5. Testicular biopsy from an azoospermic leprotic man showing ghost tubules with thickened tubular walls. There is mild cellular infiltration and a moderate increase in interstitial cells.

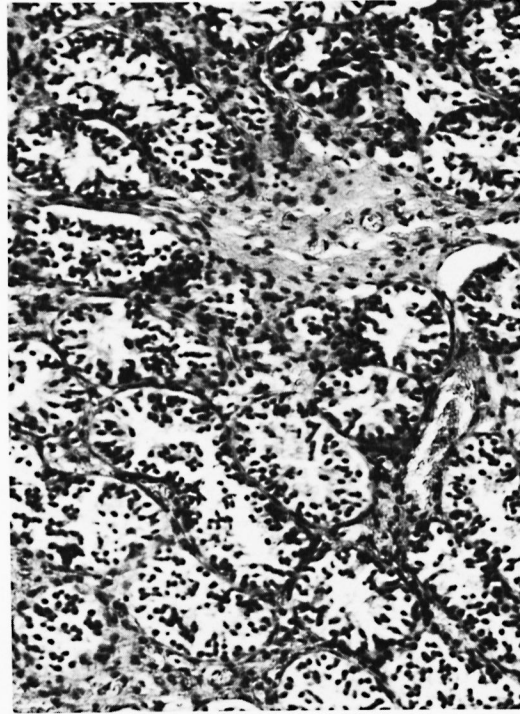


FIG. 6. Testicular biopsy from an azoospermic leprotic man showing Sertoli cells only in all tubules. Interstitial tissue shows minimal cellular infiltration and extravasation of red blood cells.

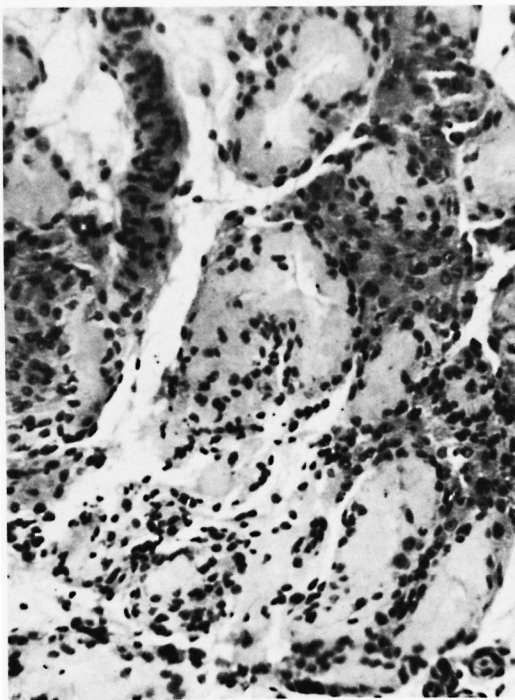


FIG. 7. Testicular biopsy from an azoospermic leprotic man with complete tubular hyalinization and increased interstitial cells with clumping.

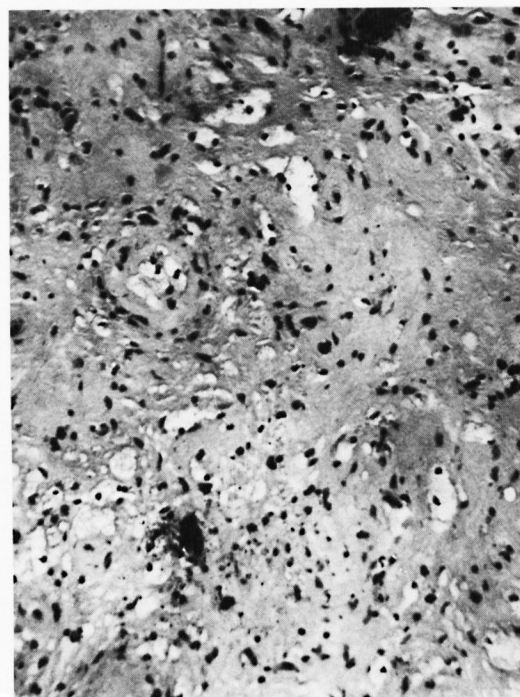


FIG. 8. Testicular biopsy from an azoospermic leprotic man with complete loss of architecture.

were moderately thickened with perivascular cellular infiltration mainly by lymphocytes and plasma cells.

In the severest form there was complete fibrosis and hyalinization of the seminiferous tubules and the structure of the tubules was completely lost. Interstitial cells were increased on some areas, vascularity was greatly diminished and cellular infiltrates were absent or minimal.

In the five cases in whom the size of the testis was more or less normal, the testicular biopsies were essentially normal with normal spermatogenesis in most of the tubules though some tubules showed focal necrosis.

**Epididymal biopsies.** In five cases biopsies from the nodules present in the tail of the epididymis showed collections of inflammatory cells, chiefly lymphocytes and plasma cells around the epididymal tubule, compressing the epididymal wall from the outside and resulting in nearly complete obstruction of the

lumen. Biopsies taken from the head of the epididymis in these five cases presented an essentially normal appearance and the lumen of the epididymal tubule was full of sperm and spermatogenic cells. The size of the testis in these cases was normal and testicular biopsies were more or less normal.

In each of the remaining five cases, epididymal biopsies taken from the tail showed similar aggregations of lymphocytes and plasma cells around the epididymal tubule but not compressing the lumen, and biopsies taken from the head yielded a normal appearance but the lumen of the epididymal tubule was empty. Testicular biopsies in these cases showed marked involvement as described above and sperm could not be detected in any of them. Testicular and epididymal specimens stained with Ziehl-Neelsen stain showed no acid-fast bacilli.

#### DISCUSSION

Testicular involvement in leprosy is a very common feature recorded by many authors.

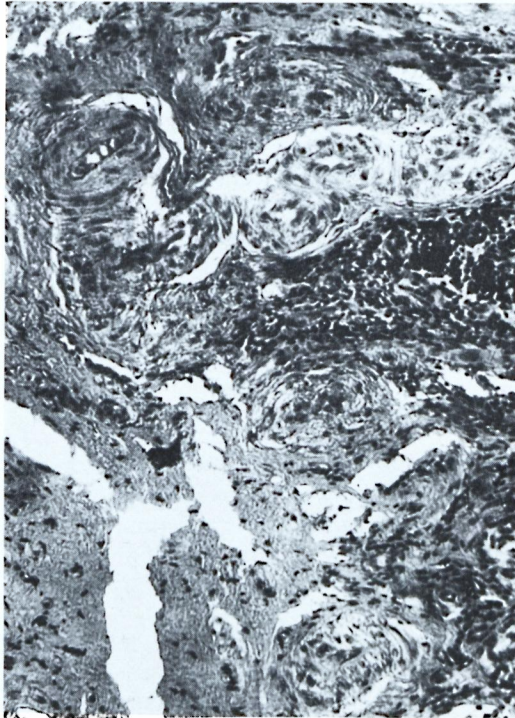


FIG. 9. Testicular biopsy from an azoospermic leprotic man with dense cellular infiltration in the interstitial tissue. There is marked thickening of the blood vessel wall with narrowing of the lumen. Seminiferous tubules show Sertoli cells only in some tubules and complete loss of architecture in some areas.

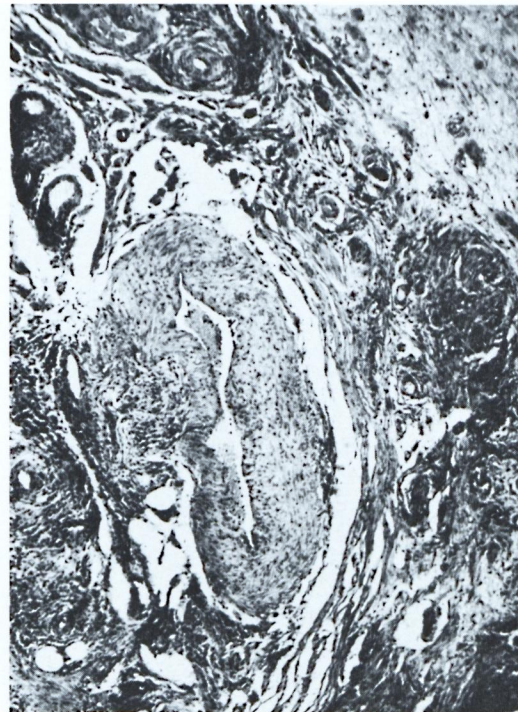

FIG. 10. Biopsy from the nodular tail of the epididymis of an azoospermic leprotic man with good testis, showing dense cellular infiltration outside the epididymal tubular wall compressing it with obliteration of the lumen.

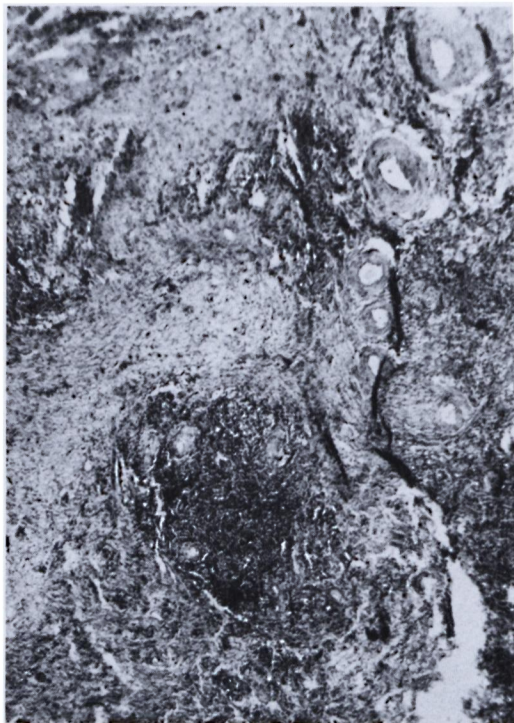

FIG. 11. Biopsy from the nodular tail of the epididymis of an azoospermic leprotic man, with small testis and collapsed epididymal head showing dense cellular infiltration outside the epididymal tubular walls but the lumina are not encroached upon.

The cause of this specific relationship between leprosy and the testis is not well understood, especially if compared with the extreme rarity of ovarian involvement. This led to the assumption that environmental temperature between the testis and the ovary may play a role (<sup>5,18</sup>). Brand (<sup>1</sup>) supported this concept by suggesting that low temperature is favorable to the growth of *M. leprae*.

Attempts have been made to differentiate leprosy involvement of the testis into stages. Grabstald and Swan (<sup>5</sup>) were the first to divide the histopathologic changes arbitrarily into three phases:

1. A vascular phase: perivascular infiltration by lymphocytes and lepra cells with many acid-fast bacilli inside these cells. The width of the vessel wall is increased at the expense of the lumen and lepromas are occasionally seen.

2. An interstitial cell phase. The major findings consist of masses of Leydig cell clumps and interstitial fibrosis. The semi-

niferous tubules are small, the basement membrane and lamina propria are considerably widened. The lumens are almost entirely filled with Sertolian syncytium. Acid-fast bacilli are not constantly present.

3. An obliterative phase. No outline of seminiferous tubules can be detected, and vascularity is greatly diminished. Acid-fast bacilli and lymphocytes are almost uniformly absent.

Job (<sup>6</sup>) differentiated the inflammatory process into the following stages: a stage of invasion, a stage of acute inflammatory reaction, and a stage of resolution and atrophy. In the present study marked testicular affection was found. We were unable to categorize these histopathologic changes into definite phases, probably because all our cases were longstanding and all of them were under treatment with antileprotic drugs.

Although previous workers have stated that epididymal affection in leprosy is uncommon (<sup>6,8</sup>), in our study about one third of the cases showed epididymal affection, either alone or in combination with testicular affection.

From our present study it is clear that testicular infection is the major etiologic factor as it was the cause of sterility in about 85% of the cases, whereas epididymal involvement was the cause in about 15% of the cases. The striking feature in these cases was that obstruction of the epididymal tubules in the globus minor was the cause of azoospermia and hence surgical treatment (i.e., epididymovasostomy) may be tried to bypass the site of obstruction.

## SUMMARY

Thirty-two cases of male infertility in patients having leprosy were studied. One case was oligospermic and the remaining 31 cases were azoospermic. Pathologic changes in the testis and epididymis are described and illustrated.

An important observation was the presence of obstruction in the tail of the epididymis in five cases and this obstruction was undoubtedly the cause of sterility in these five cases as the head of the epididymis was full of sperm and testicular biopsy was more or less normal. In the remaining 27 cases, the cause of sterility was testicular affection with fibrosis and hyalinization of the seminiferous tubules in most of the cases.

## RESUMEN

Se estudiaron 32 casos de infertilidad masculina en pacientes con lepra. Uno de los pacientes fue oligospermico y los 31 casos restantes fueron azoospermicos. Se describen e ilustran los cambios patológicos en los testículos y en los epidídimos.

Una observación importante fue la existencia de una obstrucción en la cola de los epidídimos en 5 casos. Esta obstrucción fue, sin duda, la causa de la infertilidad en estos casos ya que la cabeza de los epidídimos estaba repleta de esperma, además de que la biopsia testicular fue más o menos normal. En los 27 casos restantes, la causa de la infertilidad fue una afección testicular con fibrosis y hialinización de los túbulos seminíferos en la mayoría de los casos.

## RÉSUMÉ

On a étudié 32 cas de stérilité chez des malades de sexe masculin atteints de lèpre. Un cas était oligospermique; les 31 autres cas étaient azoospermiques. On décrit et on illustre les modifications pathologiques observées au niveau des testicules et de l'épididyme.

Une observation importante a été la présence d'une obstruction au niveau de la queue de l'épididyme chez 5 cas; cette obstruction a été manifestement la cause de la stérilité chez ces 5 malades, car la tête de l'épididyme était remplie de sperme et la biopsie testiculaire était plus ou moins normale. Chez les 27 autres cas, la cause de la stérilité était une affection testiculaire avec fibrose et hyalinisation des tubes séminifères dans la plupart des cas.

## REFERENCES

1. BRAND, P. W. Temperature variation and leprosy deformity. *In*: Transactions of the VIIth Int. Leprosy Congress, November, 1958, Tokyo: Tofu Kyokai, 1959, pp 125-129.
2. DASS, J., MURUGESAN, K., LAUMAS, K. R., DEO, M. G., KANDHARI, K. C. and RHUTAN, L. K. Androgenic status of lepromatous leprosy patients with gynecomastia. *Int. J. Lepr.* **44** (1976) 469-474.
3. FOX, H. and KNOTT, J. Leprous nodules of male genitalia. *Int. J. Lepr.* **2** (1934) 445-446.
4. FURNISS, A. L. The testis in leprosy. *Indian J. Med. Sci.* **10** (1956) 506-510.
5. GRABSTALD, H. and SWAN, L. L. Genito-urinary lesions in leprosy, with special reference to the problem of atrophy of the testes. *JAMA* **149** (1952) 1287-1291.
6. JOB, C. K. Gynecomastia and leprosy orchitis. A preliminary study. *Int. J. Lepr.* **29** (1961) 423-441.
7. MASTIN, F. R., MADDOCKS, I., BROWN, J. B. and HUDSON, B. Leprosy endocrinology. *Lancet* **2** (1968) 1320-1321.
8. POWELL, C. S. and SWAN, L. L. Leprosy: pathological changes observed in fifty consecutive necropsies. *Am. J. Pathol.* **31** (1955) 1131-1147.
9. RIDLEY, D. S. and JOPLING, W. H. A classification of leprosy for research purposes. *Lepr. Rev.* **33** (1962) 119-128.
10. SERRA, A. Localizzazioni non comuni di lepra genitale. [Uncommon localization of genital leprosy.] *Boll. Sez. Reg. Soc. Ital. Dermatol. Sifil.* **16** (1937) 375-379. Abstract in *Int. J. Lepr.* **8** (1940) 127.
11. WARREN, S. and OLSHAUSEN, K. W. Interstitial cell growths of the testicle. *Am. J. Pathol.* **19** (1943) 307-331.