

Clofazimine Enteropathy: Possible Relation to Peyer's Patches¹

Seymour Levine and Arthur Saltzman²

The use and dosage of clofazimine (B663, Lamprene®) for the treatment of erythema nodosum leprosum (ENL) are constrained by the occurrence of a drug-induced enteropathy in some individuals (1,3,4,12-14,16,17,19-22,25,28). The enteropathy has been attributed to deposition of colored clofazimine crystals in the intestinal wall. This is a logical conclusion, because the intestines are exposed to a high concentration of the drug during its initial absorption and, as a result, the bowel is often more heavily pigmented than other organs. In some reports, pigmentation increased distally in the small intestine. Clofazimine is more soluble in lipids (0.7% w/v in olive oil) than in water (0.001% w/v) (10), and it is known that some lipid-soluble drugs are readily absorbed in the intestines (27). Clofazimine, like other lipophilic molecules, is known to be absorbed through lymphatic channels as well as portal blood vessels (2), which leads to a darker pigmentation of the mesenteric lymph nodes than other nodes or other tissues.

The ileum, in addition to its role in absorption into lymphatic channels, is also the site of much of the intrinsic lymphatic tissue of the bowel—the Peyer's patches. Nevertheless, the Peyer's patches were not mentioned or described in animal studies of absorption, distribution and toxicity (7-11), or in case reports on clofazimine enteropathy, except for the case of Jagadeesan, *et al.* (17). In that patient, Peyer's patches were more inflamed and hypertrophic than the remainder of the intestines. This single observation suggested to us the possibility that Peyer's patches might be especially susceptible to the effects of clofazimine and might

have a special role in the development of an enteropathy even when the drug crystals are well tolerated by the remainder of the bowel.

The animal investigation reported here gives some substance to this hypothesis. It may serve to alert leprologists to the possible importance of Peyer's patches so that pertinent observations can be made when tissues from patients treated with clofazimine become available for observation or pathological study.

MATERIALS AND METHODS

Lewis rats of either sex, 150–300 g in weight, were fed Purina Laboratory Chow 5001 and tap water *ad libitum*. They were kept in hanging cages with wire mesh floors to reduce coprophagy.

Clofazimine was suspended at 10 mg/ml in corn oil (except as stated in the Results). A dose of 10 ml/kg body weight was administered through a gavage tube into the stomach. Multiple doses were given three times a week (Monday, Wednesday, Friday).

The rats were killed by exsanguination while under ether anesthesia. The color of the intestines, Peyer's patches, mesenteric nodes, and fat were noted. Mesenteric nodes and spleen were weighed fresh. The intestine was dipped for a minute or two in 50% acetic acid to make the Peyer's patches more conspicuous (26), and all tissues were fixed in Bouin's fluid. Both the acetic acid and the fixative intensified the colors or turned brown to green. As in man, the rat's Peyer's patches are located on the antimesenteric border of the small intestine. They are more-or-less uniformly distributed in all segments of the bowel, and the distal patches tend to be larger than the proximal patches. Most or all of them were studied histologically in cross sections of the gut embedded in paraffin and stained with hematoxylin and eosin (H&E). Peyer's patches from the apex of the cecum and the ascending colon were

¹ Received for publication on 27 January 1985; accepted for publication in revised form on 14 April 1986.

² S. Levine, M.D., Professor of Pathology; A. Saltzman, B.S., Research Associate, Pathology Department, New York Medical College, Valhalla, New York 10595, U.S.A.

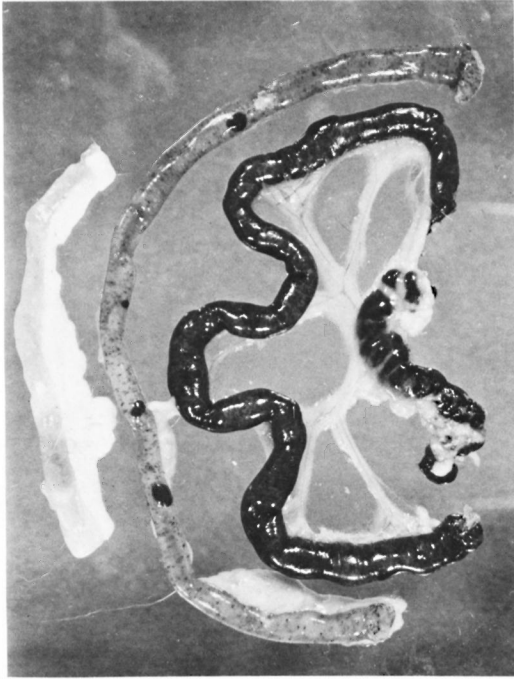


FIG. 1. Clofazimine pigmentation of rat intestines. At left is a segment of normal rat small intestine with some mesenteric fat attached. Next is a segment of jejunum showing mild diffuse darkening caused by clofazimine and striking pigmentation of four Peyer's patches which vary in size. To the right of the jejunum is a segment of ileum which is much more darkly pigmented. There are four Peyer's patches which are larger and darker than those in the jejunum but less conspicuous because of the severe diffuse pigmentation. The patches bulge on the serosal surface of the anti-mesenteric side of the intestine. At the root of the mesentery (right center) is the very dark mesenteric lymph node partly covered by pale fat.

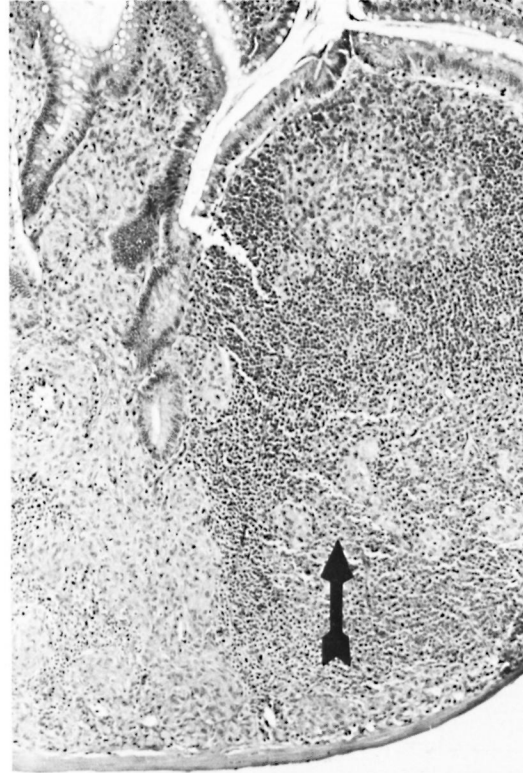


FIG. 2. Epithelioid cell granulomas in rat Peyer's patch. The granulomas (▲) are visible on the right side as rounded collections of large pale cells in and under the lymphoid follicle (around head and under tail of ▲) and under the dome. On the left side, the lymphoid tissue of the interfollicular corridor is almost completely replaced by confluent granulomas which extend into the lamina propria of the overlying villi (H&E $\times 75$).

also examined. Some rats were injected intravenously with iron-polymaltose complex (0.9 g/kg, of which 32% is iron) and the sections were studied in the Gomori stain for iron. CD-1 mice were studied also. Twenty-two different experiments were performed.

RESULTS

The rats were given six oral doses of clofazimine (100 mg/kg) during a 2-week period, and they were studied 14 days after the beginning of the treatments. Macroscopic examination of the gastrointestinal tract revealed reddish discoloration of the small intestines which increased in intensity from proximal to distal. The Peyer's patches

exhibited a similar gradient, but they were darker than the adjacent gut wall at all levels. Colonic Peyer's patches were lightly colored, but the colonic wall was uncolored. All of the body fat was orange-yellow. Mesenteric lymph nodes were much more colored than other nodes or thymus, frequently appearing black (Fig. 1).

Microscopically, there was little or no cellular reaction in the intestinal wall, but the outlines of the clofazimine crystals could be seen occasionally in the lamina propria (the drug itself having dissolved out during processing of the histologic sections). In the Peyer's patches, however, there was usually a granulomatous reaction (Fig. 2). Small clusters of epithelioid cells were present in

the indigenous lymphatic tissue of the patches, especially at the edges or base, or in the corridors between lymphoid follicles. There was no special topographic relation between the granulomas and the high endothelial venules which characteristically occur in the corridors. Most of the granulomas were located deep in the wall, close to the muscularis, but occasionally they were noted close to the mucosa, beneath the villi. Granulomas were rarely seen in the follicles or beneath the domes over the follicles even though the latter area is normally populated by phagocytic cells (^{15, 23}). Clofazimine crystals occasionally could be identified by outline in the granulomas. Each cross section of a Peyer's patch contained from 1 to 10 granulomas, somewhat less in the colonic patches.

Granulomas were far more abundant in the mesenteric lymph nodes which were frequently doubled or tripled in weight as a result (Table 1). The granulomas were found in cortex, paracortical nodules and medulla and even in the sinusoids, but they were most numerous on the edges of the T-cell dependent paracortical nodules. The granulomas in this location were larger than in the patches and were sometimes confluent, and usually contained readily detectable crystal outlines (Fig. 3). Sometimes there were clusters of pale macrophages that were so packed with crystal outlines that the usually eosinophilic cytoplasm was conspicuous by its absence. No necrosis or infiltration by polymorphonuclear leukocytes or plasma cells was detected in any location.

Granulomas in lesser numbers were seen in other pigmented lymph nodes and sometimes in the spleen, but not in the thymus. There were no granulomas in any location in the control rats given corn oil without any clofazimine.

The observations recorded above were not limited to the Lewis strain of rats. Groups of Lewis, BN and Lewis \times BN F-1 hybrid rats were given five doses of clofazimine (instead of the usual six) during a 2-week period. All three strains had a similar degree of pigmentation of Peyer's patches and other organs. Granulomas in Peyer's patches and mesenteric lymph nodes were similar in all, and the weights of the mesenteric nodes were markedly elevated (somewhat higher in the BN and hybrid strains) (Table

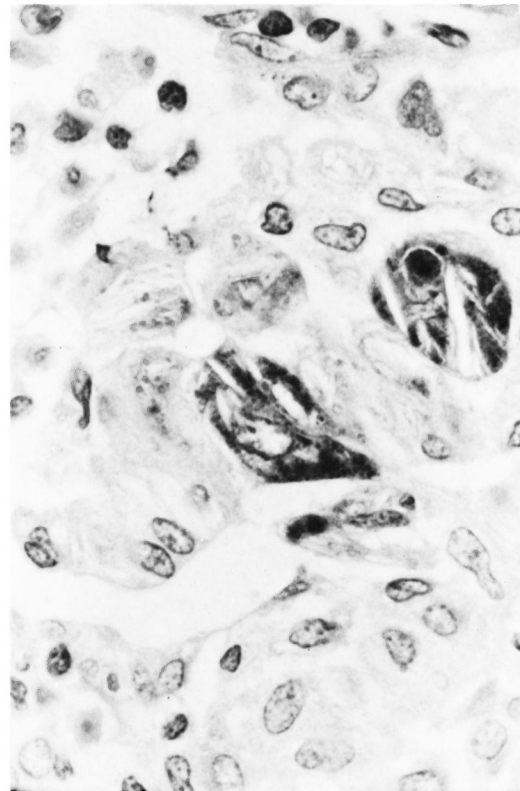


FIG. 3. Granuloma in rat mesenteric node. The clofazimine crystals are optically empty but in two cells they are outlined by darkly stained pigment derived from the injected iron-polymaltose complex. All the other epithelioid cells in the center of the photograph are also filled with crystals, but the lack of negative contrast makes it more difficult to see them (Gomori iron stain $\times 750$).

1). Similar observations were made in mice (Table 2).

In order to prove the relation of the granulomas to the reticuloendothelial system, Lewis rats treated with clofazimine orally were also given intravenous injections of an iron-maltose complex that was avidly ingested by Kupffer cells in the liver and by macrophages in the spleen and other organs. In the intestine, the iron stain revealed phagocytosis of iron by cells in the lamina propria of the villi and also by cells in various parts of the Peyer's patches. The epithelioid cells of the granulomas had taken in only a little iron or none at all. The very large number of granulomas in the mesenteric node included many that had little or no iron as well as many that did contain

TABLE 1. Clofazimine granulomas in three strains of rats.^a

Rat strain	Treatment	Granulomas			Weights ^b (g)		
		Patches ^c	Node ^d	Spleen	Rat	Node	Spleen
BN	Clofazimine	Some	Many	None	150	0.31 ± 0.01	0.49 ± 0.02
L × BN F1	Clofazimine	Some	Many	None	166	0.28 ± 0.01	0.47 ± 0.02
Lewis	Clofazimine	Some	Many	None	173	0.18 ± 0.02	0.41 ± 0.02
Lewis	Corn oil	None	None	None	171	0.14 ± 0.01	0.33 ± 0.01

^a Groups of 4 female, 9-week-old rats were given 5 oral doses of clofazimine 100 mg/kg suspended in corn oil during a 2-week period, or corn oil alone.

^b Average fresh weights of tissues taken 14 days after start of treatment are recorded, ± S.D.

^c Peyer's patches.

^d Node = entire chain of mesenteric nodes from cecum to pancreas.

iron, sometimes a high content of iron which rivaled the avid phagocytosis by medullary macrophages (Fig. 3). These granulomas with high iron content were quite numerous in rats that received the iron injection at the beginning of the first or at the beginning of the second week of clofazimine treatments, that is, when the granulomas were in the formative state. In contrast, very few granulomas absorbed iron when the iron complex was not given until 2 days before sacrifice, when granulomas were already formed, even though there was ample time for phagocytosis of iron by ordinary macrophages in the gut, lymph node, spleen, and liver. Therefore, the cells which developed into granulomas had the same ability to store iron as other reticuloendothelial cells, but once differentiated into epithelioid cells, they had decreased phagocytic ability.

The presence of iron in the crystal-laden epithelioid cells provided a morphologic bonus in that the dark-brown hemosiderin granules increased the negative contrast by which the crystal outlines could be detected in H&E stained slides. This was even better in sections stained for iron, in which the dark-blue color of the cytoplasm gave superb negative contrast images of the crystals (Fig. 3).

The development and evolution of the granulomatous reaction was studied in other experiments (Table 3). Treatment for only 1 week (three doses of clofazimine) was not enough to produce granulomas unless an additional week (without further doses) was allowed before necropsy. Presumably the extra time allowed for re-distribution of the drug from the depot in adipose tissue to the sites of granulomas. Similarly, a delay of the necropsy from 14 to 19 days after the beginning of a 2-week treatment regimen (six doses), yielded a considerable increase in granulomas.

The greatest increase in tissue reaction was produced by increasing both the number of doses and the duration of treatment. Twelve doses of clofazimine were given over a 4-week period, at the end of which the rats were necropsied. The intestine and Peyer's patches had increased pigmentation. Many villi now had numerous, easily detected crystal outlines, but no granulomatous response. In contrast, the granulomas in the Peyer's patches had increased in number, had become confluent, had invaded the lamina propria, and had virtually obliterated the interfollicular corridors. There were some granulomas in the follicles and under the dome epithelium. Even colonic Peyer's

TABLE 2. Clofazimine granulomas in mice.^a

Treatment	Granulomas			Weights ^b (g)		
	Patches	Node	Spleen	Mice	Node	Spleen
Clofazimine × 6	Many	Myriad	Rare	31	0.16 ± 0.02	0.15 ± 0.06
Clofazimine × 3	Some	Many	Rare	30	0.08 ± 0.02	0.15 ± 0.02
Corn oil × 6	None	None	None	31	0.03 ± 0.01	0.13 ± 0.03

^a Groups of 5 female Charles River CD-1 mice were given 6 oral doses during 2 weeks of clofazimine, 400 mg/kg suspended in corn oil, or only 3 doses during 1 week.

^b Average fresh weights of tissues taken 14 days after start of treatment ± S.D.

TABLE 3. Development of clofazimine granulomas.^a

Duration of treatment	Day of necropsy	Granulomas			Weights ^b (g)	
		Patches	Nodes	Spleen	Node	Spleen
Week 1	7	None	None	None	0.10 ± 0.01	0.35 ± 0.02
Week 1	14	Few	Many	None	0.26 ± 0.04	0.40 ± 0.01
Weeks 1 + 2	14	Many	Many	None	0.31 ± 0.01	0.40 ± 0.02
Weeks 1 + 2	19	Myriad	Myriad	None	0.51 ± 0.02	0.44 ± 0.02
Weeks 1, 2, 3, 4	28	Myriad	Myriad	Myriad	0.67 ± 0.02	0.89 ± 0.11

^a Groups of 4 female rats, 150–200 g in weight, were given clofazimine orally, 100 mg/kg in corn oil, 3 times weekly and necropsied on the day indicated.

^b Mean ± S.D. fresh weights of tissues.

patches had many granulomas. Mesenteric lymph nodes had a further increase in weight. Granulomas were so numerous in all areas that the nodal architecture was partially obliterated. In these animals, the spleen and liver also had many granulomas.

DISCUSSION

The observation that clofazimine granulomas in Peyer's patches continued to increase after cessation of oral treatments (Table 3) could be due to the time required for the maturation of the epithelioid cells in response to the drug that had been absorbed from the lumen. Interestingly, one of the main sites of the granulomas, the thymus-dependent corridors between follicles, is also the site at which India ink particles accumulate after absorption from the lumen⁽¹⁸⁾. However, the progression of granuloma development could also be due to accretion of clofazimine by the Peyer's patches from the bloodstream as it is gradually released from the stores in adipose tissue. It is even possible that the granuloma cells or their contents eventually migrate to the lumen, and thereby play a small part in the excretion of the drug.

Peyer's patches have an important defensive role against foreign antigens and microorganisms derived from the gut contents. However, the patches are also the initial site of invasion in certain disease states (typhoid fever, other salmonella and yersinia infections)^(5, 6), and may also be primary targets in Crohn's disease (regional ileitis)⁽²³⁾. Particulate material and soluble antigens in the intestinal contents can enter into the Peyer's patches even in the normal state⁽²⁴⁾.

In light of these facts, great importance may attach to the observation by Jagadee-

san, *et al.*⁽¹⁷⁾ that clofazimine affected the Peyer's patches more than the remainder of the gut. In the present work, we have made the same observation in experimental animals. Furthermore, we propose that the Peyer's patches may be the initial site at which clofazimine enteropathy develops. For this hypothesis we have no direct evidence. However, some support is provided by our demonstration that clofazimine elicits a granulomatous reaction in the Peyer's patches and not elsewhere in the intestines. It is immaterial whether the granuloma formation is a response to clofazimine during the initial absorption of the drug or whether the macrophages develop into epithelioid cells at a later stage due to absorption of the drug from the bloodstream (as in the spleen). The important point is that the Peyer's patches have a greater response to clofazimine than do other areas of the intestine. It is conceivable that the greater accumulation of pigment and the greater reaction to pigment could, in certain cases, develop into an injurious rather than defensive process, and trigger the development of an enteropathy.

Further exploration of this hypothesis depends on careful observations and histological studies of human tissues from surgery or autopsy. In addition, we are currently attempting to define, in animal experiments, those conditions that might turn a normal defensive reaction in Peyer's patches into the initial lesion of an enteropathy. In the present work, we have used doses of clofazimine that were far higher (on a weight basis) than usual doses given to patients. This was necessary in order to get reproducible results in a short time. However, prolonged administration of low doses is another important avenue for future work.

SUMMARY

Clofazimine administered orally to rats and mice caused pigmentation of the intestines, draining lymph nodes, fat, and other tissues and organs. Peyer's patches were always more deeply colored than the remainder of the intestine. A microscopic study revealed crystal-containing epithelioid cell granulomas in the patches and in the draining mesenteric lymph nodes but not in the remainder of the gut. During the evolution of the granulomas, some of the epithelioid cells were capable of phagocytosing an iron complex, a circumstance which made it possible to get detailed views of the clofazimine crystals in paraffin sections by negative contrast in histochemical stains for iron. The granulomas appeared after three oral treatments during 1 week, but were better developed after six or more treatments during 2 or more weeks. Similar observations were made in three strains of rats and in mice.

We hypothesize that the greater pigmentation of Peyer's patches and their granulomatous response to clofazimine might indicate a special susceptibility to toxic effects of the drug. Whether or not this susceptibility is the starting point for an enteropathy can only be determined by examination of affected human tissues and by further animal experimentation.

RESUMEN

La clofazimina administrada oralmente a ratas y ratones causó la pigmentación de los intestinos, gánglios linfáticos regionales, grasa y otros tejidos y órganos. Las placas de Peyer siempre estuvieron más coloreadas que el resto del intestino. El estudio microscópico reveló la presencia de granulomas con células epitelioides conteniendo cristales tanto en las placas como en los gánglios mesentéricos pero no en el resto del tubo digestivo. Durante la evolución de los granulomas algunas de las células epitelioides fueron capaces de fagocitar un complejo de hierro, circunstancia que permitió ver detalladamente la presencia de cristales de clofazimina en los cortes de parafina cuando se tiñeron con técnicas histoquímicas para hierro. Los granulomas aparecieron después de 3 tratamientos orales durante una semana, pero estuvieron mejor desarrollados después de 6 ó más tratamientos durante 2 ó más semanas. También se hicieron observaciones similares en 3 cepas de ratas y en ratones. Proponemos la hipótesis de que la mayor pigmentación de las placas de Peyer y su respuesta granulomatosa a la clofazimina, podrían ser indicativas de una especial susceptibilidad a los efectos tóxicos de la droga. Si esta susceptibilidad

es o no el punto de partida para una enteropatía solo podrá determinarse examinando los tejidos afectados en el humano y experimentando más con animales.

RÉSUMÉ

De la clofazimine administrée par voie orale à des rats et à des souris a entraîné la pigmentation des intestins, des ganglions lymphatiques afférents, de la graisse, ainsi que d'autres tissus et organes. Les plaques de Peyer étaient toujours plus intensément colorées que le reste de l'intestin. Une étude microscopique a révélé des granulomes à cellules épithélioïdes contenant des cristaux, dans les plaques et dans les ganglions lymphatiques mésentériques drainant la région, mais non dans les autres segments du tractus intestinal. Au cours de l'évolution des granulomes, certaines des cellules épithélioïdes acquièrent le pouvoir de phagocyter un complexe à base de fer. Ceci a dès lors permis d'obtenir des images détaillées des cristaux de clofazimine, qui apparaissent en contraste négatif dans des coupes de paraffine traitées par des colorants histochimiques fixant le fer. Les granulomes apparaissent après trois traitements administrés par voie buccale, pendant une semaine; ils sont cependant plus étendus après six traitements ou plus, administrés pendant 2 semaines ou davantage. Des observations semblables ont été faites chez trois souches de rats et de souris.

On formule l'hypothèse qu'une pigmentation plus prononcée des plaques de Peyer, ainsi que la formation d'un granulome après administration de clofazimine, pourraient révéler une susceptibilité particulière aux effets toxiques du médicament. Il serait cependant nécessaire d'examiner des tissus lésés chez l'homme, et il faudrait procéder à des expérimentations plus poussées chez l'animal, pour savoir si cette susceptibilité pourrait être à l'origine d'une manifestation intestinale clinique.

Acknowledgments. We are indebted to Ciba-Geigy Limited, Basle (Drs. T. Ahrens, K. Scheibli, H. Schroter) for the supply of clofazimine; to Hausmann Laboratories Inc., St. Gallen, Switzerland (Dr. A. Muller) for the iron-polymaltose complex; to Janine Gherson for the histologic preparations; and to Lorraine Ostrubak for preparation of the manuscript.

REFERENCES

1. ATKINSON, A. J., JR., SHEAGREN, J. N., BARBARA RUBIO, J. and KNIGHT, V. Evaluation of B.663 in human leprosy. *Int. J. Lepr.* **35** (1967) 119-127.
2. BARRY, V. C., BUGGLE, K., BYRNE, J., CONALTY, M. L. and WINDER, F. Factors influencing the antituberculosis activity of the rimino-compounds. *Bull. Int. Union Tuber.* **29** (1959) 582-593.
3. BELAUBE, P., DEVAUX, J., PIZZI, M., BOUTBOUL, R. and PRIVAT, Y. Small bowel deposition of crystals associated with the use of clofazimine (Lamprene) in the treatment of prurigo nodularis. *Int. J. Lepr.* **51** (1983) 328-330.

4. BOUTBOUL, R., DEVAUX, J., LE TREUT, Y.P., DE MICCO, C. and BRICOT, R. Entéropathie à la clofazimine. Présentation d'un cas avec étude ultrastructurale. *Gastroenterol. Clin. Biol.* **6** (1982) 43-47.
5. CARTER, P. B. Pathogenicity of *Yersinia enterocolitica* for mice. *Infect. Immun.* **11** (1975) 164-170.
6. CARTER, P. B. and COLLINS, F. M. The route of enteric infection in normal mice. *J. Exp. Med.* **139** (1974) 1189-1203.
7. CONALTY, M. L. Rimino-phenazines and the reticulo-endothelial system. *Ir. J. Med. Sci.* **491** (1966) 497-501.
8. CONALTY, M. L., BARRY, V. C. and JINA, A. The antileprosy agent B663 (clofazimine) and the reticuloendothelial system. *Int. J. Lepr.* **39** (1971) 479-492.
9. CONALTY, M. L. and JACKSON, R. D. Uptake by reticulo-endothelial cells of the riminophenazine B663 (2-P-chloroanilino-5-P-chlorophenyl-3:5-dihydro-3-isopropyliminophenazine). *Br. J. Exp. Pathol.* **43** (1962) 650-654.
10. CONALTY, M. L. and JACKSON, R. D. Intracellular accumulation and crystallisation of the antituberculosis rimino-compound, B.663. *Ann. Histochem.* **7** Suppl. **1** (1962) 221-226.
11. CONALTY, M. L. and JINA, A. G. The antileprosy agent clofazimine (B.663) in macrophages: light, electron microscope and function studies. In: *The Reticuloendothelial System and Immune Phenomena*. DiLuzio, N. R. and Flemming, K., eds. New York: Plenum Press, 1971, pp. 323-331.
12. DE MICCO, C., BOUTBOUL, R., DEVAUX, J., CHARPIN, C. and TOGA, M. Entéropathie à la clofazimine. Une observation avec étude ultrastructurale. *Ann. Pathol.* **2** (1982) 149-154.
13. DESIKAN, K. V. and BALAKRISHNAN, S. Tissue levels of clofazimine in a case of leprosy. *Lepr. Rev.* **47** (1976) 107-113.
14. DESIKAN, K. V., RAMANUJAM, K., RAMU, G. and BALAKRISHNAN, S. Autopsy findings in a case of lepromatous leprosy treated with clofazimine. *Lepr. Rev.* **46** (1975) 181-189.
15. HAMMER, R., JOEL, D. D. and LEFEVRE, M. E. Ultrastructure of macrophages of the murine Peyer's patch dome. *Exp. Cell Biol.* **51** (1983) 61-69.
16. HARVEY, R. F., HARMAN, R. R. M., BLACK, C., READ, A. E., BADDELEY, H., DAVIES, J. and ESPINER, H. J. Abdominal pain and malabsorption due to tissue deposition of clofazimine (Lamprene) crystals. *Br. J. Dermatol.* **97** Suppl. **15** (1977) 19.
17. JAGADEESAN, K., VISWESWARAN, M. K. and IYER, K. H. Acute abdomen in a patient treated with Lamprene. *Int. Surg.* **60** (1975) 208-209.
18. JEURISSEN, S. H. M., DAVID, S. and SIMINIA, T. Uptake of particulate and soluble antigens in the small intestines of the rat. *Cell Biol. Int. Rep.* **9** (1985) 523.
19. KARAT, A. B. A. Long-term follow-up of clofazimine (Lamprene) in the management of reactive phases of leprosy. *Lepr. Rev.* **46** Suppl. (1975) 105-109.
20. KARKOUCHE, B., CORTEZ, A., VAYRE, P. and CHOMETTE, G. Entéropathie à la clofazimine. À propos d'une nouvelle observation anatomoclinique. *Arch. Anat. Cytol. Pathol.* **33** (1985) 86-89.
21. KUMAR, B., BAHADUR, B., BROOR, S. L., KAUR, S., GANGWAY, D. N. and MALIK, A. K. Study of toxicity of clofazimine with special reference to structural and functional status of small intestine. *Lepr. India* **54** (1982) 246-255.
22. LAL, S., GARG, B. R. and HAMEEDULLA, A. Gastrointestinal side effects of clofazimine. *Lepr. India* **53** (1981) 285-288.
23. LEFEVRE, M. E., HAMMER, R. and JOEL, D. D. Macrophages of the small intestine: a review. *J. Reticuloendothel. Soc.* **26** (1979) 553-573.
24. LEFEVRE, M. E. and JOEL, D. D. Peyer's patch epithelium: an imperfect barrier. In: *Intestinal Toxicology*. Schiller, C. M., ed. New York: Raven Press, 1984, pp. 45-56.
25. MASON, G. H., ELLIS-PEGLER, R. B. and ARTHUR, J. F. Clofazimine and eosinophilic enteritis. *Lepr. Rev.* **48** (1977) 175-180.
26. POSKITT, D. C., DUFFEY, K., BARNETT, J., KIMPTON, W. G. and MULLER, H. K. The gut-associated lymphoid system of two species of Australian marsupial mice, *Antechinus swainsonii* and *Antechinus stuartii*. Distribution, frequency and structure of Peyer's patches and lymphoid follicles in the small and large intestine. *Aust. J. Exp. Biol. Med. Sci.* **62** (1984) 81-88.
27. SCHANKER, L. S., TOCCO, D. J., BRODIE, B. B. and HOGBEN, C. A. M. Absorption of drugs from the rat small intestine. *J. Pharmacol. Exp. Ther.* **123** (1958) 81-83.
28. YAWALKAR, S. J. and VISCHER, W. Lamprene (clofazimine) in leprosy. *Lepr. Rev.* **10** (1979) 135-144. Also *Lamprene (Clofazimine) in Leprosy*. Basle: CIBA-GEIGY Ltd., 2nd ed, 1984.