

Histopathological Examination of Skin Biopsies from an Epidemiological Study of Leprosy in Northern Malawi¹

A. Colin McDougall, Jorg M. Ponnighaus,
and Paul E. M. Fine²

Histopathological examination of skin biopsies is well recognized to be of value in the diagnosis and classification of clinically difficult presentations of leprosy. But the role of histopathology in epidemiological studies is less widely appreciated. The literature contains several papers describing the histopathological features of leprosy as revealed in biopsy series collected in different areas of the world, but most of these have been drawn from hospitals, treatment centers, or selected patient groups, and they are by no means representative of all leprosy in their "parent" populations. There are very few examples in which biopsies have been routinely collected from all cases or suspects identified in a population survey. One was the series of biopsies collected during the follow-up of the Karimui BCG trial in Papua New Guinea (¹⁹). We are not aware of publications describing a representative series of leprosy biopsies from an African population and, therefore, believe it would be of interest to report our findings on just such a series as has been collected in the Lepra Evaluation Project (LEP) in Northern Malawi. In doing so, we hope to clarify two major points: a) What is the role of histopathology in an epidemiological study, and b) What is the "true" distribution of the various types of leprosy in this area of the world?

¹ Received for publication on 4 February 1986; accepted for publication in revised form on 28 July 1986.

² A. C. McDougall, M.D., F.R.C.P., Consultant in Clinical Research (Leprosy), Department of Dermatology, The Slade Hospital, Oxford OX3 7JH, England. J. M. Ponnighaus, Dr.med., D.T.P.H., Director, Lepra Evaluation Project, P.O. Box 46, Chilumba, Karonga District, Malawi. P. E. M. Fine, V.M.D., Ph.D., Senior Lecturer, Ross Institute, London School of Hygiene and Tropical Medicine, Keppel Street, London WC1E 7HT, England.

Reprint requests to Dr. Fine.

The LEP was set up in 1979 as a longitudinal study directed toward the identification of risk factors in leprosy and the assessment of different approaches to control. In particular the project aimed to: a) clarify the mode of transmission of *Mycobacterium leprae*; b) identify risk factors for clinical and subclinical leprosy, including genetic, contact, and other environmental factors; c) evaluate the effect of existing leprosy control methods and of BCG vaccination in controlling the disease; and d) investigate the suitability of the area for vaccine studies.

A pilot study was carried out in 1979 to determine the feasibility of the study and to develop field procedures. The main study started in 1980. The first survey during which 112,000 people were examined (almost the entire population of Karonga District) was completed in mid-1984. Plans have been made to undertake a second survey during the years 1986–1989.

This report describes 686 biopsies from 664 individuals suspected of or thought to have ongoing clinical leprosy when they were interviewed and examined by the LEP between 1980 and 1983. These individuals will be called "suspects" throughout this paper since it would be misleading to call them leprosy "patients." Some of these biopsies were the subject of preliminary reports presented at the XII International Leprosy Congress in Delhi (^{1, 11}). Biopsies taken from individuals already on antileprosy treatment or in whom a relapse was suspected have been excluded from this analysis.

SUBJECTS AND METHODS

The general methods involved in the LEP will be described in detail in a separate publication. For the purpose of this presentation, it is important to note that the project entailed the systematic examination of a to-

tal population. Initial examinations were carried out by trained paramedical Leprosy Control Assistants (LCAs) who referred all suspects to the medical officer (JMP). Clinical diagnoses were based upon examination of suspects by the medical officer who also graded his level of confidence that the individual had leprosy, using a descending certainty scale: "leprosy certain" = 5; "leprosy extremely likely" = 4; "leprosy most likely" = 3; "leprosy to be considered seriously" = 2; "possible leprosy" = 1; "not leprosy" = 0. After deciding upon the diagnosis and on the level of clinical certainty, the medical officer attempted to obtain a biopsy for one of the following reasons:

For documentary purposes: If clinically there was no real doubt about the diagnosis of leprosy (clinical certainty 4 or 5), biopsies were nevertheless requested to document diagnosis and classification unless the age of the suspect or the site of the lesion made this inappropriate (e.g., children under ten, a lesion solely on the face of a young woman, etc.). Such contraindications to taking a biopsy or refusal of the suspect to have a biopsy taken did not interfere with the decision to initiate antileprosy treatment. There were nine refusals in this group during the period covered in this paper.

For leprosy-diagnostic purposes: If leprosy seemed the most likely clinical diagnosis but there was lack of definite evidence (clinical certainty grading 3), or considerable doubt (clinical certainty 2), or if there was only a very vague suspicion that the diagnosis was leprosy (clinical certainty 1), then biopsies were attempted for diagnostic purposes. In this situation, individuals who refused a biopsy were not offered antileprosy treatment. It is probable that the less likely the diagnosis of leprosy appeared to the examiner the less pressure was exerted on a reluctant individual to change his or her mind. On the other hand, if the diagnosis of leprosy seemed "most likely," the village headman or the area party chairman was occasionally asked to help to persuade a suspect to have a biopsy taken. There were 20 refusals in this group. In this group, if age or the site of the lesion made the taking of a biopsy unacceptable, the individuals were usually "kept under observation." Whenever feasible, they were also re-examined by

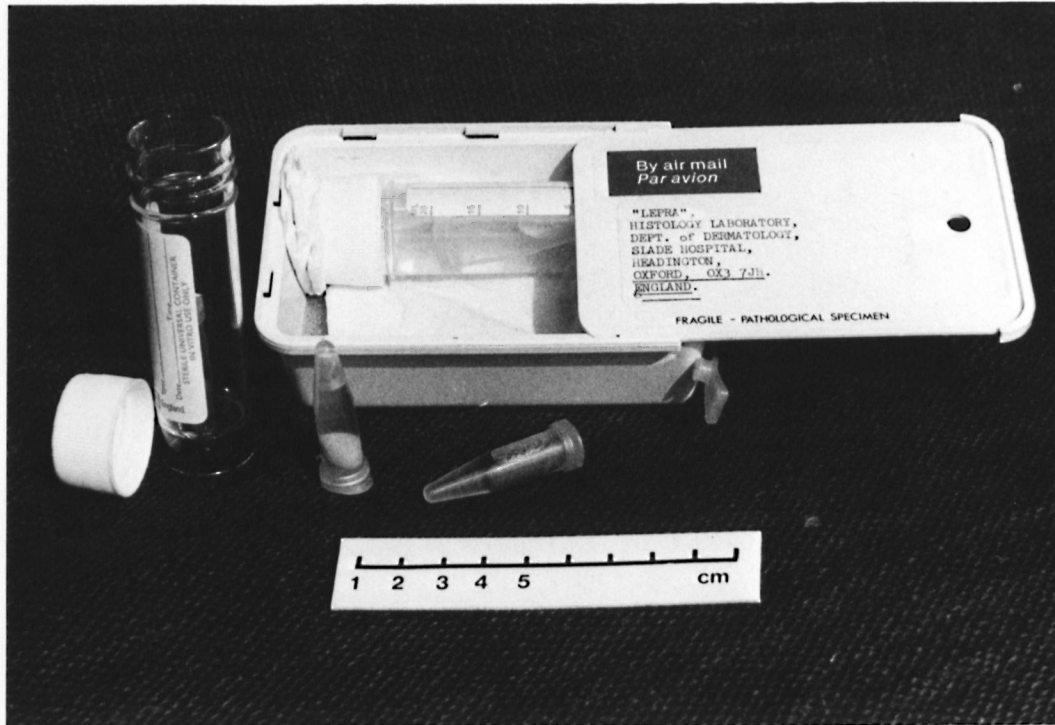
another medical officer before a final decision was made whether or not to recommend antileprosy treatment.

For diagnostic purposes other than leprosy: Very occasionally a biopsy was also taken to obtain advice from the histopathologist on a skin condition not thought to be leprosy. Coding in such cases was either "possibly leprosy" (=clinical certainty 1) or "not leprosy" (=clinical certainty 0).

All of the biopsies included in this series were obtained with a 4-mm (or, rarely, 3-mm) disposable punch (Steiffel Laboratories). They were taken under local anesthesia, with particular attention to the removal of tissue of adequate depth. The specimen was transferred to fixative as gently as possible with the use of forceps. Fixation throughout has been in a modification of formol-Zenker⁽¹⁰⁾ with transfer to 70% alcohol after 18 to 24 hr.

All histopathological processing was carried out in Oxford, U.K. Biopsies had been dispatched from Malawi to Oxford in small plastic vials (Eppendorf, 1.5 ml) packed in a durable plastic box as shown in The Figure (8). No specimen has been lost since the project started in 1979, although a few have arrived desiccated due to leaky vials. None of these is included in the analyses presented in this paper. Specimens were mounted in paraffin, cut at 5 μ m, and stained with hematoxylin and eosin (H&E) and with the Fite-Faraco modification of the Ziehl-Neelsen stain for acid-fast bacilli (AFB)⁽⁵⁾. Between 10 and 20 sections were cut from each block.

All of the specimens were examined by one histopathologist (ACM). The criteria for the diagnosis and classification of leprosy were those described by Ridley and Jopling^(16, 17) and by Ridley^(14, 15). A conscious effort was made to adhere to this system and to refrain from introducing personal views. The histopathologist recorded his findings using a pre-defined protocol for diagnosis, classification, certainty grading, and (where appropriate) the bacterial index (BI) found in the sections (Table 1). This protocol was introduced in November 1981, and biopsies already examined and reported on by then were coded by the histopathologist on the basis of the wording of his original report. Certainty grades 1B, 1, 2A, 2, or 3 were not



THE FIGURE. Plastic box and small plastic vials (Eppendorf, 1.5 ml) for the postal dispatch of skin biopsies from Malawi to Oxford. Although not essential, the plastic vials may be put into plastic "universal" bottles, with screw cap as an additional safeguard against leakage. (With acknowledgment to *Leprosy Review* for permission to reproduce this figure from Volume 53, 1982, 67-68.)

TABLE 1. *LEP histopathology report protocol as used in this investigation.*

I. Biopsy quality:
S = Satisfactory.
U = Unsatisfactory (cite reason).
II. Diagnosis:
1A = Leprosy confirmed beyond reasonable doubt.
1B = Leprosy almost certain but slight element of doubt.
(1) = Unable to select between 1A and 1B.
2A = Consistent with but not diagnostic of leprosy.
2B = Pathological and possibly due to leprosy, but lacking specific diagnostic criteria. Implies less evidence of leprosy than in 2A.
(2) = Unable to select between 2A and 2B.
3A = Definitely pathological but completely nonspecific.
3B = Normal or near normal tissue—minimal changes only.
(3) = Unable to discriminate between 3A and 3B.
4 = Pathological but indicative of a specific disease other than leprosy. If so, please specify.
5 = "Other"—any unusual or unforeseen circumstance. If so, please specify.
III. Classification:
e.g., Ind, TT, BT, BB, BL, LL.
IV. Bacillary content:
N = No bacilli found within usual examination period.
BI = (1-6) if bacilli found.
D = Doubtful findings (e.g., a few granules).

used. The histopathologist used the certainty grading 1A if there was a characteristic cell infiltrate with nerve involvement and/or the presence of AFB. Certainty grade 2B was used to cover cases with epithelioid granulomas, or nondescript granulomas, which had no evidence of nerve involvement and where no bacilli could be found. Grade 3A indicated pathological changes indicative neither of leprosy nor any other dermatological condition. The use of the 3B category usually indicated a few histiocytes in the upper dermis or occasionally mixed lymphocytes and histiocytes. Grade 4 was used as per definition.

For the purpose of this study, the term "indeterminate" (for which there is as yet no internationally agreed definition) was used to indicate that there was evidence of leprosy but insufficient findings on which to proceed to a classification within the Ridley-Jopling scale.

RESULTS

Biopsies were obtained from 95% of all new suspects found during the population survey. Twenty-two repeat biopsies are included in this analysis, 20 of which were taken because the clinician was not satisfied with the initial histopathological certainty grading or the histopathological classification.

Table 2 shows the age-sex distribution of all 664 suspects included in this study; 42% of them were males and 58%, females. The preponderance of females is statistically significant ($p < 0.0001$), and is most notable in the older age groups. The histopathologist provided a classification for 49.3% of biopsies from males and for 53.4% of biopsies from females ($p > 0.1$). The proportion of classified biopsies considered multibacillary was much higher for males (20/138 = 14.5%) than for females (4/205 = 2.0%). This difference is statistically highly significant ($\chi^2 = 18.1$, $p < 0.001$).

The distributions of levels of clinical and histopathological certainty are shown in Table 3. The histopathologist found definite evidence of leprosy (histopathology code 1A) in 354 (52%) of the 686 biopsies, and in 117 (17%) he found pathological changes, usually epithelioid cell granulomas, which were considered as possibly due to leprosy

TABLE 2. Distribution of 664 subjects included in this study, by age, sex and histopathological classification.

Period of birth	Approx. age in 1980	Males				Females				Totals			
		Pauci-Ind. ^a -BT/BB	Multi-BB-LL	Not class.	Total	Pauci-Ind.-BT/BB	Multi-BB-LL	Not class.	Total	Pauci-Ind.-BT/BB	Multi-BB-LL	Not class.	Total
>1964	0-16	37	2	17	56	43	1	23	67	80	3	40	123
1958-1963	17-22	12	2	19	33	17	0	18	35	29	2	37	68
1946-1957	23-34	22	4	33	59	38	1	36	75	60	5	69	134
1934-1945	35-46	24	7	35	66	36	2	41	79	60	9	76	145
1914-1933	47-66	19	4	33	56	49	0	47	96	68	4	80	152
1900-1913	67-80	4	1	5	10	18	0	14	32	22	1	19	42
	All ages	118	20	142	280	201	4	179	384	319	24	321	664

^a Ind. = indeterminate.

TABLE 3. *Distribution of levels of clinical and histopathological certainty for 686 biopsies included in this study.*

Level of histopathological certainty	Codes	Level of clinical certainty					Total	
		Not leprosy (0)	Possibly (1)	To be considered seriously (2)	Most likely (3)	Extremely likely (4)		Certain (5)
Level of histopathological certainty	1A		16 ^a (12.6%)	45 (40.5%)	87 (46.8%)	164 (77.7%)	42 (89.4%)	354 (51.6%)
	1B							
	2A							
	2B		25 (19.7%)	16 (14.4%)	50 (26.9%)	23 (10.9%)	3 (6.4%)	117 (17.1%)
	3A	1 (25.0%)	63 (49.6%)	36 (32.4%)	40 (21.5%)	22 (10.4%)	2 (4.3%)	164 (23.9%)
	3B		17 (13.4%)	13 (11.7%)	8 (4.3%)	2 (0.9%)		40 (5.8%)
	4	3 (75.0%)	6 (4.7%)	1 (0.9%)	1 (0.5%)			11 (1.6%)
	Total	4 (100.0%)	127 (100.0%)	111 (100.0%)	186 (100.0%)	211 (100.0%)	47 (100.0%)	686 (100%)
	(Row percent)	(0.6%)	(18.5%)	(16.2%)	(27.1%)	(30.8%)	(6.9%)	(100%)

^a For each combination, the top figure gives the number of biopsies and the lower figure (in parentheses) gives the column percentage.

but lacking convincing criteria for that diagnosis (histopathology code 2B). The remaining 215 biopsies (31%) were considered to show no evidence of leprosy (histopathology codes 3A, 3B, or 4). On the other hand, the clinician thought there was definite evidence of leprosy ("certain" or "extremely likely") in 258 (37.6%) of the suspects and some good evidence (termed "most likely") in a further 186 (27.1%) suspects. In only 26 (10%) of the 258 suspects in whom the clinician thought he had found definite evidence did the histopathologist find no evidence of leprosy (histopathology code 3A or 3B). But the histopathologist found definite evidence of leprosy (code 1A) in 16 (12.6%) of 127 biopsies taken from lesions which the clinician thought only "possibly" due to leprosy.

In 11 biopsies (1.6%) the histopathologist reported definite evidence of some dermatological condition other than leprosy, e.g., dermatitis, fungal infection, lichen planus, skin tuberculosis, or granuloma annulare (histopathology code 4). A patient of particular interest who presented with multiple skin lesions, somewhat suggestive of bor-

derline (dimorphous) leprosy but without anesthesia or enlarged nerves, was shown on histopathological examination of a repeat biopsy to have mycosis fungoides. A detailed description of this case, which has, to our knowledge, not been described so far in Malawi, is in preparation.

Table 4 shows a breakdown of classification by both the clinician and the histopathologist. Out of the total of 354 histopathological classifications, 322 (91%) were either TT, TT/BT, or BT. The polar tuberculoid (TT) cases included several with striking evidence of erosion of the epidermis, central caseation of a nerve bundle, fibrinoid necrosis in the dermis, and massive enlargement of a nerve bundle in the deep dermis with almost total replacement by the infiltrating granuloma. In BT biopsies, nerves in the deep dermis were frequently heavily involved, with virtual replacement of the endoneurial zone by epithelioid cells and lymphocytes and infiltration of the perineurium by numerous lymphocytes.

In the remaining groups, BB (mid-borderline), BL (borderline-lepromatous), and

TABLE 4. Correlation between clinical and histopathological classification of the 354 biopsies for which classification was provided by both the clinician and the histopathologist.

		Biopsy classification									Total	
		Ind. ^a	TT	TT/ BT	BT	BT/ BB	BB	BB/ BL	BL	BL/ LL		LL
Clinical certainty	Ind. ^a		1	2					1 (a) ^b		4	
	TT		21	20	27						68	
	TT/BT	3	23	20	59					1 (b)	106	
	BT		14	26	93	3					136	
	N ^c				1			1 (c)			2	
	BB		1 (d)		13	1	4	1	2	1 (e)	1 (f)	24
	BL	1 (g)			1 (h)			2	3	1		8
	BL/LL								1		3	4
	LL										2	2
	Not leprosy											
	Total	4	60	68	194	4	4	4	7	3	6	354

^a Ind. = indeterminate.

^b Individuals over whom there was some disagreement, labeled (a) through (h), are discussed in the text.

^c Neural.

LL (lepromatous) the findings were as described by Ridley and Jopling, with appropriate numbers of AFB on Fite-Faraco staining. Histoid leprosy, as originally described by Wade (²¹), was not encountered.

There were only eight (2%) major discrepancies between clinician and histopathologist among the 354 classifications provided by the histopathologist, and these are described in the Discussion section.

DISCUSSION

We will concentrate in the discussion on the two questions posed at the outset of the paper: the role of histopathology in an epidemiological study of leprosy, and the true type distribution of leprosy in this population.

The disposable punch proved highly satisfactory. It facilitated the taking of biopsies in the field, especially since no sutures were required. It was well tolerated by the subjects themselves, with only 29 (4.2%) persons refusing out of a total of 693 from whom a biopsy was requested during the period analyzed in this report. (Of course, this percentage reflects more than the biopsy instrument alone.) The biopsies themselves were cleanly cut and nontraumatized, comparing well with specimens obtained by scalpel. Throughout this series, the importance of a deep biopsy, including the lower and preferably also the subdermis, was apparent. A very high percentage of the biop-

sies in this study carried a small amount of subdermal fat, indicating that the entire dermis was included for examination. On at least 20 occasions, a definite diagnosis of leprosy and an accurate classification would not have been possible but for the depth of the punch biopsy which revealed a lower or subdermal nerve. We would also mention that the use of formol-Zenker fixative with transfer to alcohol resulted in the vastly better preservation of collagen and cytological detail than is seen with simple Formalin fixation.

Without the additional information provided by routine histopathology of these suspects many cases would have been missed, and this could interfere seriously with the analysis of other data collected by the project as a whole. It is extremely difficult to make precise estimates of the level of underdiagnosis or overdiagnosis of leprosy in any study, given the nature of the criteria upon which diagnosis depends, but the combination of both clinical and histopathological evidence may increase both the sensitivity and the specificity of the overall diagnostic procedure. A degree of clinical underdiagnosis is difficult to avoid in a total population survey, given that many paucibacillary leprosy lesions will be found at an early, arrested, or regressing stage in their evolution. Indeed, this is a major rationale for taking biopsies from suspects. But histopathological underdiagnosis will also

occur, either because a biopsy or the examined sections fail to include a pathognomonic lesion or through human error. In this series, such a situation is indicated by the 26 suspects in whom the clinician considered leprosy either "extremely likely" or "certain" but in whom the histopathologists could find no evidence of leprosy. In this context, it should be appreciated that the clinician's certainty was based upon all clinical findings and not only upon the lesion from which the biopsy was taken. No repeat biopsies were obtained from these 26 suspects since all were put on antileprosy treatment on clinical grounds at the time the initial biopsy was taken. However, repeat biopsies were obtained from 20 of the remaining 178 individuals whose initial biopsy was considered to lack any specific evidence of leprosy (code 3A or 3B), and in 5 of these the second biopsy was reported to show definite evidence of leprosy. This might indicate that at least 2.8% (5/178) of the negative histopathology reports in this series were "false" negatives.

Overdiagnosis on either clinical or histopathological examination is, on the other hand, much more difficult to demonstrate. There are two reasons for this. First, positive evidence generally carries more weight than does a negative diagnosis or the absence of findings, and in such circumstances one tends to attribute the difference to underdiagnosing on the part of the examiner who did not find the evidence. Secondly, positive findings generally lead to the initiation of treatment which, in turn, provides a further explanation for any negative findings thereafter.

A few additional comments are in order concerning the group designated by the histopathologist as "pathological and possibly due to leprosy, but lacking specific diagnostic criteria" (code 2B). A considerable number of these showed well-developed epithelioid cell granulomas, but without AFB and with normal nerves. Although perhaps erring on the side of caution in a part of Africa where leprosy might be considered the most likely cause of such findings, it was nevertheless thought impossible to eliminate sarcoidosis, tuberculosis, granuloma multiforme (Mkar disease) or foreign body reaction, all of which occur in Malawi

(¹³ and Molesworth, B. D., personal communication, 1979), on the examination of the available sections alone. On the basis of combined clinical and histopathological findings, granuloma multiforme (⁹) had seriously to be considered in at least two cases in this series although the pathological features were not fully developed. Schulz (¹⁸) and Rampen (¹³) have already drawn attention to the very wide range of dermatological conditions which may occur in this part of Africa, many of which may be confused with leprosy, and Jacyk (⁶) has commented on the occurrence of sarcoidosis in West Africa and the need to distinguish it carefully from granuloma multiforme or leprosy. Skin infections by various "unidentified" mycobacteria may also occur (²), and some of these may respond to antileprosy drugs. It was felt that such diagnostic alternatives should be kept in mind rather than to diagnose leprosy on the basis of inconclusive biopsy findings. Nevertheless, the 2B category, which comprised 17% of all biopsies in the present series, is bound to contain a substantial number of true leprosy cases in which the examination of up to 20 sections did not reveal definite evidence of the disease. In this context, it is worth noting that out of 19 repeat biopsies thus far taken from individuals initially classed by the histopathologist as 2B (some taken after the cut-off date selected for this investigation), 14 revealed definite evidence of leprosy.

With regard to the classification of leprosy, our results indicate that histopathology may contribute little to an experienced clinician who has the support of a laboratory for slit-skin smear examinations. This conclusion is consistent with other studies (^{7, 12, 20}). In this respect, however, it is of interest to note that major discrepancies in classification did occur eight times in this series (letters (a) through (h), Table 4). The following brief notes provide the background to these discrepancies.

(a) 140759-4: This middle-aged man was first reviewed by JMP in September 1982. Slit-skin smears were negative at the time, and no biopsy was taken because it was thought that if it was leprosy at all, the classification should be BL leprosy. However, that seemed to be ruled out by the slit-skin

smear result. On a later review in March 1983, a biopsy was taken and a clinical classification of "indeterminate leprosy" was made in the absence of a more recent slit-skin smear result. The biopsy showed changes typical of BL leprosy with numerous bacilli, mainly in histiocytes and nerves.

(b) 123796-6: This young man had only a single erythematous lesion (plaque) in the face. The classification of BT leprosy in reaction was made before the result of slit-skin smears was known (average BI = 2.3). The biopsy revealed typical LL leprosy with large numbers of bacilli (BI = 6).

(c) 124060-2: Clinical findings were anesthesia of both feet, ulcer under the head of metatarsalis I. Both superficial peroneal nerves slightly but not definitely enlarged. No skin lesions. Slit-skin smears were negative on two occasions. A split-nerve biopsy was taken from the left superficial peroneal nerve. This revealed considerable pathology with a classification BB/BL and many bacilli.

(d) 122728-8: This young woman presented herself with numerous hypopigmented macules and plaques, and three specimens were taken from three different lesions. The histopathological results were: 1) inconclusive (S 2A N, see Table 1); 2) TT-leprosy (S 1A TT N); and 3) BT-leprosy (S 1A BT N).

(e) 127375-9: This man had received antileprosy treatment in the government leprosarium in Kochirira for more than 10 years, starting about 1960. Clinical findings were minimal and slit-skin smears were negative. The biopsy showed old established LL changes with no evidence of activity and no bacilli.

(f) 172038-5: Also treated in Kochirira, probably since 1965. Slit-skin smears were still positive (average BI = 1). Considered in retrospect, this individual should have been classified clinically as at least BL leprosy. The biopsy showed quite extensive LL leprosy with bacilli in macrophages and nerves.

(g) 154458-6: This young man had numerous macules, anesthetic right sole, and ulcers under his right foot. From the appearance, the diagnosis was BL leprosy although slit-skin smears turned out to be negative. Sections revealed changes in lower

dermal nerves, indicating leprosy, but classification was impossible to determine. No bacilli, thus "indeterminate."

(h) 171928-6: Another young man with plaques only. The clinical classification of BL leprosy was made before the result of slit-skin smears was known (BI = 0). The biopsy revealed BT leprosy, including typical changes in lower dermal nerves.

These notes illustrate a variety of combinations of circumstances which arise in a study such as this. We would, in particular, call attention to suspects (c) and (d) as examples of problems for the clinician and the histopathologist.

As can be seen in Table 4, dual or "split" classifications (TT/BT, BT/BB, BB/BL, BL/LL) were used for a considerable proportion (22%) of cases. We wish to emphasize that this was due to a genuine difficulty in deciding between classifications, and is not intended as an attempt to create new groups. Ridley has drawn attention to BT and TT changes in the same biopsy⁽¹⁴⁾ and also to the occasional need for a classification such as "BT-BL"⁽¹⁵⁾. In addition, in the present study the use of a 4-mm or even 3-mm punch in the taking of biopsies may in some cases have resulted in insufficient material being available for histopathological examination for selection of a single classification.

The high proportion of cases classified as tuberculoid (TT, TT/BT, BT) in this series deserves comment. The extent to which it reflects the "true" type distribution of leprosy in this population is dependent upon the way in which the cases were ascertained. It is recognized that the proportion tuberculoid, or paucibacillary, will be higher among new (incident) cases than among prevalent cases, insofar as some paucibacillary cases heal without trace and some may downgrade to multibacillary disease⁽²²⁾. The case series ascertained in the first LEP survey and described in this report represents a mixture of incident and prevalent cases. Leprosy control had been in operation in the area since 1973, and had already identified a large number of cases, almost entirely by self-reporting. Our series thus contains a higher proportion of paucibacillary cases than would have been the case if there had been no prior leprosy control in

the area, given that individuals with paucibacillary disease are less likely to self-report than are those with multibacillary disease (LEP, unpublished data). On the other hand, many of the cases ascertained in the survey, and included in this series, were longstanding and cannot be considered as "new" or incident cases. To this extent, the current series underestimates the "true" proportion of paucibacillary disease in the population as a whole. It is difficult to estimate the relative magnitudes of these two tendencies. Taken together, they must counteract each other to some extent, and thus our estimate of the proportion of paucibacillary of leprosy in this population should be approximately correct.

The proportion of paucibacillary classifications by the histopathologist was significantly higher for females (98%) than for males (85%). This difference is consistent with, although rather more extreme, than that reported in many other populations⁽³⁾. The overall female excess in this series is not a reflection of an unbalanced sex ratio in the population.

The results of this study illustrate that the diagnosis of leprosy by either clinician or histopathologist presents far greater difficulty than does its classification. This issue is discussed in detail in a companion publication on the comparability of diagnosis and classification by different histopathologists⁽⁴⁾.

In conclusion, we find that the routine taking and examination of skin biopsies, using a disposable 4-mm punch, has proven to be an important supplement to the field diagnosis of leprosy in the Leprosy Evaluation Project. It has confirmed the clinical classification of 98% of the cases for whom the histopathologist found evidence of leprosy, and given further evidence for the very high proportion of paucibacillary disease in this part of the world.

SUMMARY

This report describes the histopathological findings in 686 biopsies obtained from 664 individuals during the course of a total population survey for leprosy in Northern Malawi. The criteria for the selection of cases for biopsy, the biopsy technique using a 4-mm punch, fixation method, transport of

biopsies from Africa to the United Kingdom, and the method of coding histopathological results are described. Fifty-two percent (354) of the biopsies showed definite evidence of leprosy on histopathological examination. Using the Ridley-Jopling system, these biopsies were classified as follows: TT = 60 (17%); TT/BT = 68 (19%); BT = 194 (55%); BT/BB = 4 (1%); BB = 4 (1%); BB/BL = 4 (1%); BL = 7 (2%); BL/LL = 3 (1%); LL = 6 (2%). In addition, four (1%) biopsies were classified as "indeterminate" on histology, meaning that although there was evidence of leprosy it was not possible to provide a precise classification. A further 117 biopsies (17% of the total) had abnormal changes, often including epithelioid cell granulomas, possibly caused by leprosy but lacking specific criteria for that diagnosis. Finally, 203 (30%) of the biopsies had nonspecific (often minimal) changes, and 11 (2%) of the total showed evidence of some dermatological condition other than leprosy. Histopathological examination of biopsies in this study confirmed the clinical classification in 98% of the cases in which the histopathologist found evidence of leprosy, and supplied further evidence for the very high proportion of paucibacillary cases in this part of the world.

RESUMEN

Este trabajo describe los hallazgos histopatológicos en 686 biopsias obtenidas de 664 individuos durante el curso de un estudio poblacional sobre la lepra en Malawi del Norte. Se describen los criterios para la selección de casos, la técnica de biopsia usando un sacabocados de 4 mm, el método de fijación, el transporte de las biopsias de Africa al Reino Unido, y el método de clasificación de los resultados histopatológicos. El 52% (354) de las biopsias mostraron evidencias histopatológicas definitivas de la lepra. Usando la clasificación de Ridley-Jopling, estas biopsias se identificaron como sigue: 60 TT (17%), 68 TT/BT (19%), 194 BT (55%), 4 BT/BB (1%), 4 BB (1%), 4 BB/BL (1%), 7 BL (2%), 3 BL/LL (1%) y 6 LL (2%). Además, 4 biopsias (1%) se consideraron como indeterminadas porque aunque hubieron evidencias de la lepra, no fue posible hacer una clasificación precisa. Ciento diecisiete biopsias (17% del total) tuvieron cambios anormales, incluyendo granulomas epitelioides, probablemente causados por la lepra pero carentes de los criterios específicos para precisar el diagnóstico. Finalmente, 203 biopsias (30%) tuvieron cambios no es-

pecíficos (a menudo mínimos) y 11 (2%) del total mostraron evidencias de alguna condición dermatológica diferente a la lepra. El examen histopatológico de las biopsias confirmó la clasificación clínica en el 98% de los casos y proporcionó evidencias de la alta proporción de casos paucibacilares en esta parte del mundo.

RÉSUMÉ

Ce rapport décrit les observations histopathologiques faites dans 686 biopsies obtenues chez 664 individus au cours d'une enquête sur la lèpre portant sur une population prise dans son entier au Nord du Malawi. Les critères établis pour choisir les cas à biopsier, la technique de biopsie basée sur l'utilisation d'un poinçon de 4 mm, les méthodes de fixation, le transport des biopsies d'Afrique au Royaume-Uni, de même que la méthode employée pour coder les résultats histopathologiques, sont décrits. Dans cinquante deux pour cent (354) des biopsies, on a mis en évidence des caractéristiques indubitables de lèpre sur la base de l'examen histopathologique. Les biopsies ont été classées de la manière suivante sur l'échelle de Ridley-Jopling: TT = 60 (17%); TT/BT = 68 (19%); BT = 194 (55%); BT/BB = 4 (1%); BB/BL = 4 (1%); BL = 7 (2%); BL/LL = 3 (1%); LL = 6 (2%). De plus, quatre (1%) biopsies ont été classées comme "indéterminées" sur la base de l'histologie, ce qui signifie qu'il n'était pas possible d'aboutir à une classification précise, encore que ces coupes présentaient des signes nets de lèpre. De plus, 117 biopsies (17% du total) montraient des modifications anormales, qui consistaient souvent en granulomes à cellules épithélioïdes, qui auraient pu être causées par la lèpre mais ne répondaient pas aux critères spécifiques nécessaires pour établir ce diagnostic. Enfin, 203 biopsies (30%) présentaient des modifications non spécifiques, souvent minimales, et 11 (2% du total) montraient des signes de conditions dermatologiques autres que la lèpre. L'examen histopathologique des biopsies pratiquées au cours de cette étude a confirmé la classification clinique dans 98% des cas chez lesquels l'histopathologiste avait observé des signes de lèpre. Ceci, s'il le faut, témoigne en faveur de la très proportion de cas paucibacillaires dans cette partie du monde.

Acknowledgments. The Leprosy Evaluation Project is funded primarily by the British Leprosy Relief Association (LEPRA), with assistance from the Overseas Development Association and the IMMLEP component of the WHO/TDR Programme. The authors are grateful to these agencies and to the government of the Republic of Malawi for their interest and active support. Special thanks are due to the LEP field staff in Malawi, in particular Mr. Kayesera, Mr. Mwamondwe, Mr. Nkhosa Mwafulirwa, Mr. Msosa, Ms. Rosie Hau, and Mr. Munthali for their efforts in discovering the leprosy suspects discussed in this paper. We acknowledge Dr. Vincent Gooskens, previously Government

Dermatologist in Malawi, for having first suggested the use of disposable punches for this study, and Dr. Gjal Boerrigter for his help and advice in many circumstances. The study would not have been possible without the technical skill of Richard Jones and Kate Schomberg in processing the biopsies. Dr. Neil Smith kindly provided an additional histopathological opinion on some of the biopsies, and we thank Nick Maine for assistance with the analyses and Brenda Slessor for preparation of the manuscript.

REFERENCES

1. BOERRIGTER, F. G., MCDUGALL, A. C. and PONNIGHAUS, J. M. The value of histopathology in a leprosy control programme. *Int. J. Lepr.* **52** (1984) 746.
2. FELDMAN, R. A. and HERSHFIELD, E. Mycobacterial skin infection by an unidentified species. *Ann. Intern. Med.* **80** (1974) 445-452.
3. FINE, P. E. M. Leprosy: the epidemiology of a slow bacterium. *Epidemiol. Rev.* **4** (1982) 161-188.
4. FINE, P. E. M., JOB, C. K., MCDUGALL, A. C., MEYERS, W. M. and PONNIGHAUS, J. M. Comparability among histopathologists in the diagnosis and classification of leprosy patients with lesions suspected of leprosy in Malawi. *Int. J. Lepr.* **54** (1986) 614-625.
5. FITE, G. L., CAMBRE, P. J. and TURNER, M. H. Procedure for demonstrating lepra bacilli on paraffin sections. *Arch. Pathol.* **42** (1947) 616-624.
6. JACYK, W. K. Sarcoidosis in West Africa; a report of eight Nigerian patients with cutaneous lesions. *Trop. Geogr. Med.* **36** (1984) 231-236.
7. JERATH, V. P. and DESAI, S. R. Diversities in clinical and histopathological classification in leprosy. *Lepr. India* **54** (1982) 130-134.
8. JONES, R. L. and PONNIGHAUS, J. M. The transport of histopathological specimens by air mail. *Lepr. Rev.* **53** (1982) 67-68.
9. LEIKER, D. L. Granuloma multiforme; a new skin disease resembling leprosy. *Int. J. Lepr.* **32** (1964) 368-376.
10. LOWY, L. Processing of biopsies for leprosy bacilli. *J. Med. Lab. Technol.* **13** (1956) 558-560.
11. MCDUGALL, A. C., PONNIGHAUS, J. M., FINE, P. E. M. and ZONENA, K. H. The histopathological examination of skin biopsies from an epidemiological study of leprosy in Northern Malawi. *Int. J. Lepr.* **52** (1984) 756.
12. MEYERS, W. M., HEGGIE, C. D., KAY, T. L., STAPLE, E. M. and KVERNES, S. The Ridley-Jopling five-group classification of leprosy—correlations of parameters of the classification in 1,429 leprosy patients. *Int. J. Lepr.* **47** (1979) 683-684.
13. RAMPEN, F. The dermatological clinic in a leprosy control scheme; 10 years' experience in Malawi. *Lepr. Rev.* **49** (1979) 141-147.
14. RIDLEY, D. S. Histopathological classification and

- immunological spectrum of leprosy. Bull. WHO **51** (1974) 451-465.
15. RIDLEY, D. S. *Skin Biopsy in Leprosy; Histological Interpretation and Clinical Application*. 2nd ed. Basle: CIBA-GEIGY Ltd., 1985.
 16. RIDLEY, D. S. and JOPLING, W. H. A classification of leprosy for research purposes. *Lepr. Rev.* **33** (1962) 119-128.
 17. RIDLEY, D. S. and JOPLING, W. H. Classification of leprosy according to immunity; a five-group system. *Int. J. Lepr.* **34** (1966) 255-273.
 18. SCHULZ, E. J. Skin disorders in Black South Africans. *S. Afr. Med. J.* **62** (1982) 864-867.
 19. SCOTT, G. L., RUSSELL, D. A., BOUGHTON, C. R. and VINCEN, D. R. Untreated leprosy; probability of shifts in Ridley-Jopling classification. Development of "flares" or disappearance of clinically apparent disease. *Int. J. Lepr.* **44** (1976) 110-122.
 20. SEHGAL, V. N., REGE, V. L. and REY, M. Correlation between clinical and histopathological classification in leprosy. *Int. J. Lepr.* **45** (1977) 278-280.
 21. WADE, H. W. The histoid variety of lepromatous leprosy. *Int. J. Lepr.* **31** (1963) 129-142.
 22. WORLD HEALTH ORGANIZATION STUDY GROUP. Epidemiology of leprosy in relation to control. Geneva: World Health Organization, 1985. WHO Tech. Rep. Ser. 716.